

2

ABNORMAL PREMENOPAUSAL UTERINE BLEEDING

Theodore O'Connell

In women of childbearing age, abnormal uterine bleeding includes any change in menstrual period frequency, duration, or amount of flow, as well as bleeding between cycles. A menstrual cycle of fewer than 21 days or more than 35 days is considered abnormal. Likewise, a menstrual flow of fewer than 2 days or more than 7 days is abnormal.

When abnormal uterine bleeding is evaluated (Figs. 2-1 and 2-2), it is important to make certain that the bleeding is not from a gastrointestinal or urinary source. Once it is clear that the bleeding is vaginal, pregnancy should be the first consideration in women of childbearing age. After pregnancy has been ruled out, iatrogenic causes of abnormal uterine bleeding should be considered. Medications linked to abnormal premenopausal uterine bleeding are outlined later in this chapter. After pregnancy and iatrogenic causes have been excluded, systemic conditions should be considered. These systemic causes and the suggested workup, outlined later in the chapter, include thyroid, hematologic, pituitary, hepatic, adrenal, and hypothalamic disorders.

Genital tract disease should be considered. Diagnoses that should be considered include cervical pathologic processes, sexually transmitted disease, trauma, uterine fibroids, endometrial polyps, endometrial hyperplasia and atypia, and endometrial cancer.

Dysfunctional uterine bleeding occurs during the childbearing years, but the diagnosis is one of exclusion that should be made only after pregnancy, iatrogenic causes, systemic conditions, and obvious genital tract disease have been ruled out.

Further evaluation of abnormal uterine bleeding depends on the patient's age and the presence of risk factors for endometrial cancer. These risk factors include anovulatory cycles, obesity, nulliparity, age greater than 35 years, and tamoxifen therapy. Anovulation occurs at the extremes of reproductive age (during the postmenarchal and perimenopausal periods).

Because endometrial cancer is rare in 15- to 18-year-old girls, dysfunctional uterine bleeding in most adolescents can be treated safely with hormone therapy and observation, without the need for diagnostic testing.

Of cases of endometrial carcinoma, 20% to 25% occur before menopause, and the risk of developing endometrial cancer increases with age. Thus, the American College of Obstetricians and Gynecologists recommends endometrial evaluation in women aged 35 and older who have abnormal uterine bleeding. Endometrial evaluation is also recommended for patients younger than 35 who are at high risk for

endometrial cancer: Women with vaginal bleeding who are younger than 35 years and have no identifiable risk factors for neoplasia can be assumed to have dysfunctional bleeding and treated accordingly. However, if bleeding continues in a patient at low risk for neoplasia despite medical management, endometrial evaluation is indicated.

Endometrial evaluation may be accomplished by endometrial biopsy, transvaginal ultrasonography, saline-infusion sonohysterography, dilatation and curettage, or hysteroscopy with biopsy. Endometrial evaluation usually proceeds with endometrial biopsy, which can be performed in the office using the Pipelle technique. The efficacy of transvaginal ultrasonography in the premenopausal population is not as well defined as it is in postmenopausal women. For this reason, endometrial evaluation usually begins with endometrial biopsy. However, because endometrial biopsy may miss a significant percentage of benign endometrial lesions such as polyps and fibroids, some clinicians recommend proceeding to saline-infusion sonohysterography or dilatation and curettage with hysteroscopy.

Medications Linked to Abnormal Premenopausal Uterine Bleeding

- Anticoagulants
- Antipsychotics
- Corticosteroids
- Herbal and other supplements
- Hormonal contraception
- Intrauterine devices
- Selective serotonin reuptake inhibitors
- Tamoxifen
- Thyroid hormone replacement

Causes of Abnormal Premenopausal Uterine Bleeding

- Adenomyosis
- Adrenal hyperplasia and Cushing disease
- Atrophic endometrium
- Bleeding disorders
- Cervical carcinoma
- Cervical dysplasia
- Cervical polyp
- Cervicitis
- Dysfunctional uterine bleeding

Endometrial carcinoma
Endometrial hyperplasia
Endometrial polyp
Endometritis
Estrogen-producing ovarian tumors
Hyperprolactinemia
Hypothalamic suppression (stress, weight loss, excessive exercise)
Hyperthyroidism
Hypothyroidism
Leiomyomata
Leiomyosarcoma
Leukemia
Liver failure
Medications and herbal supplements
Myometritis
Pituitary adenoma
Polycystic ovary syndrome
Pregnancy (intrauterine or ectopic)
Pregnancy-related conditions

- Abruptio placentae
- Ectopic pregnancy
- Miscarriage
- Placenta previa
- Trophoblastic disease

Renal disease
Salpingitis
Testosterone-producing ovarian tumors
Thrombocytopenia
Trauma (foreign body, abrasions, lacerations, sexual abuse or assault)

Key Historical Features

- ✓ Frequency, duration, and severity of flow
- ✓ Normal cycle pattern
- ✓ Method of contraception
- ✓ Compliance with hormonal contraception if it is being used
- ✓ Sexual activity

- ✓ Postcoital bleeding
- ✓ Pelvic pain
- ✓ Easy bruising or tendency to bleed
- ✓ Jaundice or history of hepatitis
- ✓ Stress
- ✓ Excessive exercise
- ✓ Medical history
- ✓ Surgical history
- ✓ Obstetric and gynecologic history
- ✓ Medications
- ✓ Systemic symptoms
 - Fatigue
 - Nausea or vomiting
 - Weight gain or weight loss
 - Heat or cold intolerance
 - Constipation
 - Sweating
 - Palpitations
 - Urinary frequency
 - Easy bruising
 - Jaundice
 - Hirsutism
 - Acne
 - Headache
 - Galactorrhea
 - Visual field disturbance

Key Physical Findings

- ✓ Assessment of vital signs
- ✓ General assessment of health and evaluation for obesity
- ✓ Search for evidence of eating disorders
- ✓ Thyroid examination for thyromegaly or thyroid tenderness
- ✓ Cardiovascular examination for tachycardia

- ✓ Skin examination for acne or acanthosis nigricans (signs of polycystic ovary syndrome or diabetes mellitus); also evaluation for bruising as a sign of coagulopathy and for jaundice
- ✓ Breast examination for galactorrhea
- ✓ Pelvic examination to evaluate for vulvar or vaginal lesions, signs of trauma, cervical polyps or dysplasia, cervical motion tenderness, uterine enlargement, uterine tenderness, or adnexal masses
- ✓ Extremity examination for edema

Suggested Work-Up

Pregnancy test	To evaluate for pregnancy
Pap smear	To evaluate for cervical dysplasia
Cultures for gonorrhea and chlamydia or nucleic acid amplification tests	If infection is suspected or the patient is at risk for sexually transmitted disease
Complete blood cell count (CBC)	If bleeding is heavy or prolonged and anemia is suspected
Endometrial biopsy <i>or</i> transvaginal ultrasonography <i>or</i> saline infusion sonohysterography <i>or</i> dilatation and curettage with hysteroscopy	Recommended in women aged 35 and older with abnormal uterine bleeding; also recommended for patients younger than 35 who are at high risk for endometrial cancer and for patients at low risk who continue bleeding abnormally despite medical management. See previous text for an explanation of benefits and drawbacks of each.

Additional Work-Up

Transvaginal ultrasonography	If there is uterine enlargement or an adnexal mass
Thyroid-stimulating hormone (TSH) measurement	If hypothyroidism or hyperthyroidism is suspected
Prolactin level measurement	If pituitary adenoma or hyperprolactinemia is suspected

Blood glucose measurement	If diabetes mellitus is suspected
Liver function tests and prothrombin time measurement	If liver disease is suspected
CBC with measurements of platelet count, prothrombin time, and partial thromboplastin time	If coagulopathy is suspected
Dehydroepiandrosterone sulfate (DHEAS), free testosterone, and 17 α -hydroxyprogesterone measurements	If ovarian or adrenal tumor is suspected on the basis of signs of hyperandrogenism
von Willebrand factor measurement	If von Willebrand disease is suspected
Blood urea nitrogen (BUN), creatinine, and TSH measurements	If edema is present
Colposcopy	If cervical dysplasia is found on Pap smear

FURTHER READING

- ACOG Community on Practice Bulletins—American College of Obstetrics and Gynecology: ACOG practice bulletin: management of anovulatory bleeding. *Int J Gynaecol Obstet* 2001;73:263-271.
- Albers JR, Hull SH, Wesley RM: Abnormal uterine bleeding. *Am Fam Physician* 2004;69:1915-1926.
- Apgar BS: Dysmenorrhea and dysfunctional uterine bleeding. *Prim Care* 1997;24:161-178.
- Chen BH, Giudice LC: Dysfunctional uterine bleeding. *West J Med* 1998;169:280-284.
- Davidson KG, Dubinsky TJ: Ultrasonographic evaluation of the endometrium in postmenopausal vaginal bleeding. *Radiol Clin North Am* 2003;41:769-780.
- Elford KJ, Spence JE: The forgotten female: pediatric and adolescent gynecological concerns and their reproductive consequences. *J Pediatr Adolesc Gynecol* 2002;15:65-77.
- Goldstein SR: Abnormal uterine bleeding: the role of ultrasound. *Radiol Clin North Am* 2005;44:901-910.
- Goldstein SR, Zeltser I, Horan CK, et al: Ultrasonography-based triage for perimenopausal patients with abnormal uterine bleeding. *Am J Obstet Gynecol* 1997;177:102-108.
- Goodman A: Abnormal genital tract bleeding. *Clin Cornerstone* 2000;3(1):25-35.
- Kilbourn C, Richards C: Abnormal uterine bleeding. *Postgrad Med* 2001;109:137-140.
- Schrager S: Abnormal uterine bleeding associated with hormonal contraception. *Am Fam Physician* 2002;65:2073-2080.
- Smith-Bindman R, Kerlikowske K, Feldstein VA, et al: Endovaginal ultrasound to exclude endometrial cancer and other endometrial abnormalities. *JAMA* 1998;280:1510-1517.
- Tabor A, Watt HC, Wald NJ: Endometrial thickness as a test for endometrial cancer in women with postmenopausal vaginal bleeding. *Obstet Gynecol* 2002;99:663-670.

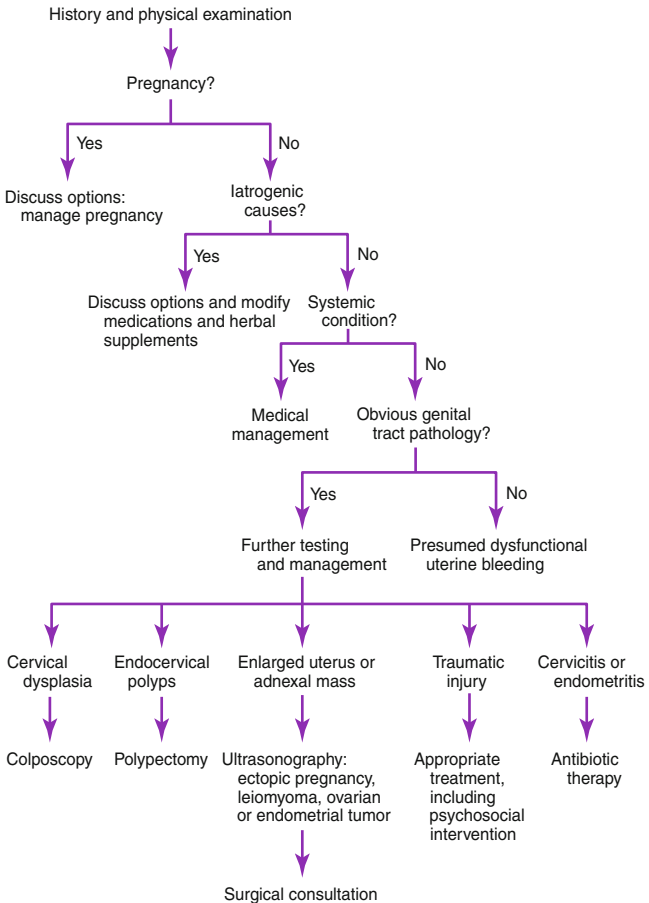


Figure 2-1. Abnormal uterine bleeding in women of childbearing age. Sequential steps through the differential diagnosis of abnormal uterine bleeding in women of childbearing age.

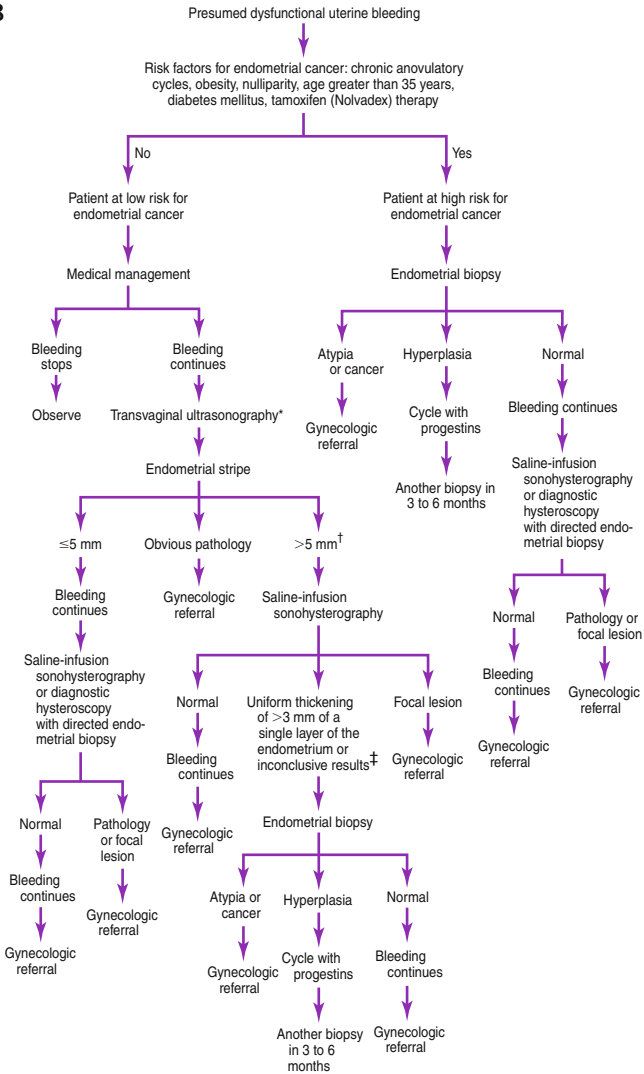


Figure 2-2. Presumed dysfunctional uterine bleeding in women of childbearing age: evaluation based on risk factors for endometrial cancer.

*Transvaginal ultrasonography ideally is performed during the late proliferative stage.
†Some investigators consider an endometrial stripe of 7 to 8 mm or larger to be abnormal in premenopausal or perimenopausal women.
‡These determinants are based on information from Goldstein SR, Zeltser I, Horan CK, Snyder JR, Schwartz LB. Ultrasonography-based triage for perimenopausal patients with abnormal uterine bleeding. *Am J Obstet Gynecol* 1997;177:102-108.